

Eimeria macusaniensis and *Eimeria ivitaensis* co-infection in fatal cases of diarrhoea in young alpacas (*Lama pacos*) in Peru

C. A. PALACIOS, R. A. PERALES,
A. E. CHAVERA, M. T. LOPEZ, W. U. BRAGA,
M. MORO

PARASITIC diseases are one of the main health problems in the alpaca (*Lama pacos*) and llama (*Lama glama*) herds of the Peruvian Andes. Of these, coccidiosis due to *Eimeria* species is considered to be the main cause of fatality in young alpacas and llamas (Ameghino and DeMartini 1991). Five different coccidian species have been described in llamas and alpacas: *Eimeria alpaca*, *Eimeria lamae* and *Eimeria punoensis*, which affect the villous epithelium (Guerrero 1967), *Eimeria macusaniensis*, which affects the crypt epithelium (Guerrero 1967, Rosadio and Ameghino 1994), and *Eimeria ivitaensis* (Leguia and Casas 1998), which is of unknown pathogenicity. This short communication describes cases of diarrhoea leading to death associated with infections with two *Eimeria* species in young alpacas in Peru.

During the dry season (from July to August) in 2002, seven four- to five-month-old alpacas were presented with sudden onset of watery to bloody diarrhoea followed by dehydration, emaciation and death. The alpacas were from an Andean alpaca herd, which lived at Marangani, Cusco-Peru, 4200 m above sea level. At postmortem examination, the small intestine (duodenum, jejunum and ileum) and large intestine (caecum, colon and rectum) were sampled and fixed for 48 hours in 10 per cent neutral-buffered formalin. The tissues were embedded in paraffin, sectioned at 5 µm and stained with haematoxylin and eosin according to standard techniques. All measurements and coccidian identifications were performed in fixed tissues as described by Guerrero and others (1970) and Leguia and Casas (1998).

Gross pathological alterations were observed in the jejunal and ileal mucosa. In the jejunum, the mucosa was oedematous, thickened, exfoliated and slightly reddened. Numerous white, slightly raised, nodular foci were also present in the mucosa near the ileum, with areas of intense infection in the crypt and villous epithelium caused by gamonts and developing oocysts. In most cases the Peyer's patches were up to 4 cm in diameter.

Microscopically, *E. macusaniensis* and *E. ivitaensis* schizonts were identified within the crypt and villous epithelial cells. *E. ivitaensis* were restricted to the jejunum and ileum (Fig 1). Immature stages of the *E. macusaniensis* lifecycle were present in the mucosa of the jejunum, ileum and caecum, and in the ascending colon; the associated mucosa contained subacute to chronic lesions, which were characterised by shortening and fusion of the villi. In some areas there was a total loss of epithelial mucosa, with exposure of the basal lamina. The lamina propria from the caecum and colon was moderately to severely infiltrated by lymphocytes, plasma cells, eosinophils and neutrophils, with focal haemorrhages and the presence of immature microgamonts. The crypt epithelium of the jejunum and the ileum was hyperplastic and hypertrophic, with large, hypochromatic nuclei. *E. ivitaensis* schizont forms were associated with more severe morphological changes

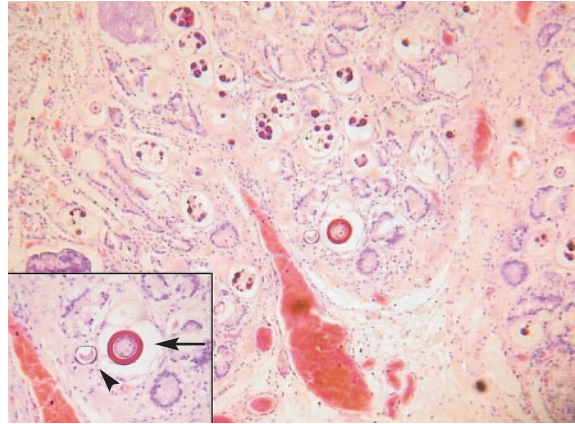


FIG 1: Enteritis associated with massive infiltration of macrogamonts and immature oocysts of *Eimeria macusaniensis* and *Eimeria ivitaensis* in the crypts of Lieberkühn. Haematoxylin and eosin. $\times 100$. Inset: Higher magnification showing *E. macusaniensis* (arrow) and *E. ivitaensis* (arrowhead). Haematoxylin and eosin. $\times 200$

compared with *E. macusaniensis*. The villi in *E. ivitaensis*-infected areas were necrotic, with the lamina propria severely infiltrated by mononuclear cells and neutrophils. There was increased mitosis of epithelial cells.

E. macusaniensis and *E. ivitaensis* macrogamonts were located in the cytoplasm, between the nucleus and the basal membrane of epithelial cells of the caecal and colonic crypts. They were ovoid in shape and located within a parasitophorous vacuole bounded by one membrane. The immature macrogamonts were morphologically indistinct for both *Eimeria* species, with 4 to 5 µm thick capsules, abundant cytoplasm, large, basophilic nuclei and average sizes of 30.9 \times 28.6 µm, with a range (sd) of 16.5 to 38 (5.28) \times 15 to 40 (5.25) µm in 10 specimens. The morphology of the developing macrogamonts of *E. macusaniensis* and *E. ivitaensis* changed according to their degree of maturation and the observation of many inclusion bodies in the cytoplasm that differed in size and number (Figs 2a, b). Mature macrogamonts of *E. ivitaensis* (Fig 2c) had 12 to 22 lightly basophilic inclusion bodies, which were ovoid and had a diameter of approximately 2 to 3.5 µm. Mature macrogamonts of *E. macusaniensis* (Fig 2d) had six to seven eosinophilic inclusion bodies, which were ovoid and approximately 13 to 18 µm in diameter.

The microgamonts of both coccidian species were morphologically similar. They were localised mainly in the base and neck of the crypts of Lieberkühn. Immature oocysts of *E. macusaniensis* were localised mainly in the top of the crypts and in some cases in the bottom (Fig 1), with piriform shapes and sizes similar to those described by Guerrero (1967). Immature oocysts of *E. ivitaensis* were also localised mainly in the top of the crypts, but had ellipsoidal forms, 3 to 5 µm thick capsules with three membranes, and an average size of 56.9 \times 45.6 µm (range [sd] 45 to 75 [9.89] \times 39 to 55 [5.5] µm) in 10 specimens.

Coccidiosis in alpacas is subclinical, or appears as soft to bloody diarrhoea and acute death (Rojas 1990, Ameghino and DeMartini 1991). Co-infection with multiple species of *Eimeria* is common in alpacas, with *E. macusaniensis* and *E. lamae* considered to be the most pathogenic (Guerrero and others 1970). Although *E. ivitaensis* has only relatively recently been described (Leguia and Casas 1998), evidence for *E. macusaniensis* and *E. ivitaensis* co-infection was found in the guts of mummified llamas from a 2700-year-old culture called Chiribaya in Peru, suggesting the simultaneous presence of these two species in the past (Martinson and others 2003).

Veterinary Record (2006)
158, 344-345

C. A. Palacios, DVM,
R. A. Perales, DVM, MS,
A. E. Chavera, DVM, MS,
W. U. Braga, DVM, MS,
Laboratorio de
Histopatología,
M. T. Lopez, DVM, MS,
PhD,
Laboratorio de
Parasitología,
Departamento de Salud
Animal y Salud Pública,
Facultad de Medicina
Veterinaria, Universidad
Nacional Mayor
de San Marcos,
Av Circunvalacion cdr 28
s/n San Borja, Apartado
03-2067, Lima, Peru
M. Moro, DVM, MPH,
PhD,
Department of Diagnostic
Medicine/Pathobiology,
College of Veterinary
Medicine, Kansas State
University, 1800 Denison
Avenue, Manhattan,
KS 66506, USA

Dr Braga is also at the
Department of Diagnostic
Medicine/Pathobiology,
College of Veterinary
Medicine, Kansas State
University, 1800 Denison
Avenue, Manhattan,
KS 66506, USA

Correspondence to
Dr Moro

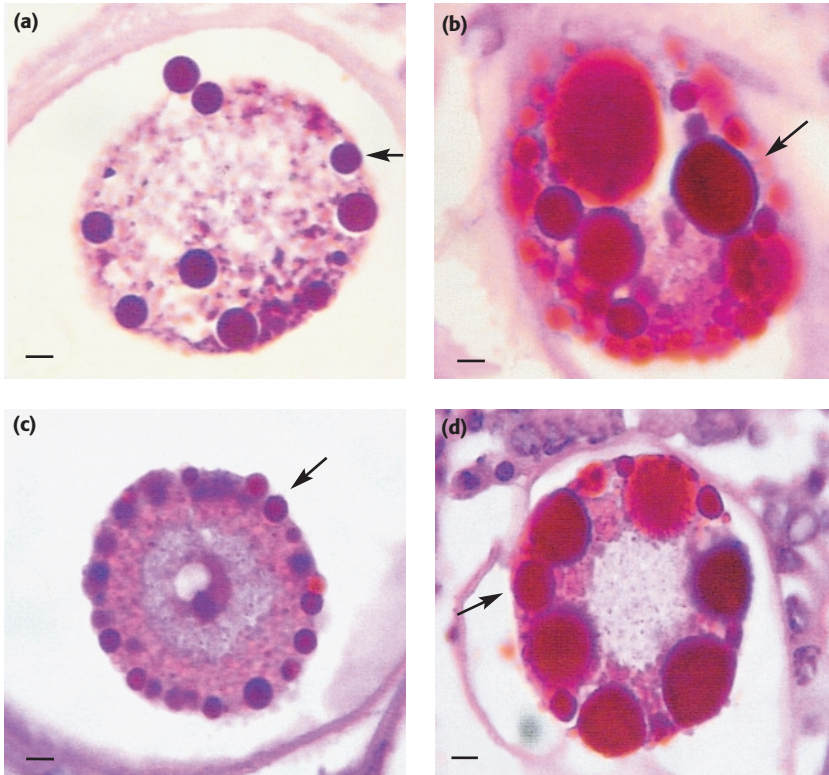


FIG 2: Comparison of (a) growing macrogamonts of *Eimeria ivitaensis* and (b) growing macrogamonts of *Eimeria macusaniensis*, and (c) mature macrogamonts of *E ivitaensis* and (d) mature macrogamonts of *E macusaniensis*. Both species are of a similar size, but differ in the number and size of inclusion bodies (arrows). Haematoxylin and eosin. $\times 1000$

The present findings describe, for the first time, *E ivitaensis* and *E macusaniensis* co-infection causing death in seven young alpacas, showing an important cytopathic effect when both parasites massively infect the jejunal and ileal crypts. *E ivitaensis* and *E macusaniensis* co-infection should be considered in the diagnosis of coccidian infections in young alpacas.

ACKNOWLEDGEMENTS

The authors thank Mr Timoteo Huisa, La Raya-UNSAAC alpaca ranch administrator, and Dr Wilber Garcia, IVITA-Marangani research station director, for their technical assistance, and Dr Guillermo Leguia and Dr Derek Mosier, for helpful review and discussion of the present work.

References

- AMEGHINO, E. F. & DEMARTINI, J. (1991) Coccidiosis. In *Mortalidad de Crias de Alpaca*. Lima, Centro de Investigacion IVITA-UNMSM. pp 71-112
- GUERRERO, C. (1967) Coccidia (Protozoa: Eimeriidae) of the alpaca (*Lama pacos*). *Journal of Protozoology* **14**, 613-616
- GUERRERO, C., ALVA, J., LEGUIA, G. & BAZALAR, H. (1970) Prevalencia de coccidias en alpacas (*Lama pacos*). *Revista de la Facultad de Medicina Veterinaria, Universidad Nacional Mayor de San Marcos* **4**, 84-90
- LEGUIA, G. & CASAS, E. (1998) *Eimeria ivitaensis* (Protozoa: Eimeriidae) en alpacas (*Lama pacos*). *Revista Peruana de Parasitologia* **13**, 59-61
- MARTINSON, E., REINHARD, K. J. & BUIKSTRA, J. E. (2003) Pathoecology of Chiribaya parasitism. *Memórias do Instituto Oswaldo Cruz* **98** (Suppl 1), 195-205
- ROJAS, M. (1990) Eimeriosis. In *Parasitismo de los Animales Domesticos*. 1st edn. Lima, Maijosa. pp 301-310
- ROSADIO, R. H. & AMEGHINO, E. F. (1994) Coccidial infections in neonatal Peruvian alpacas. *Veterinary Record* **135**, 459-460