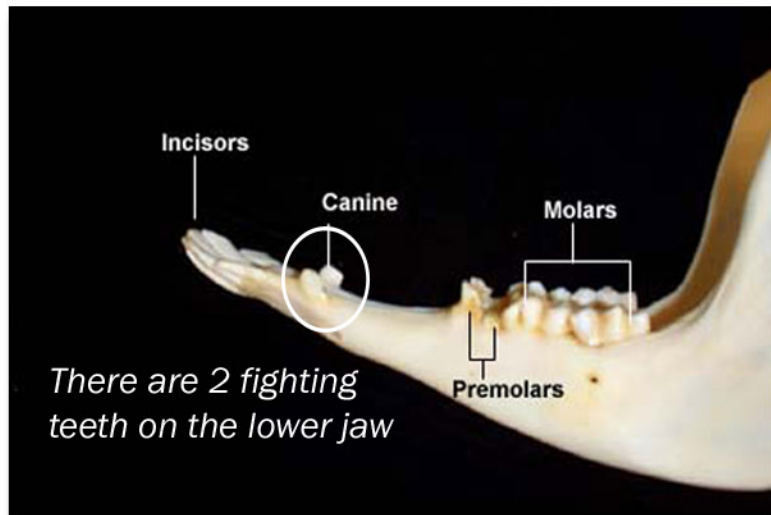
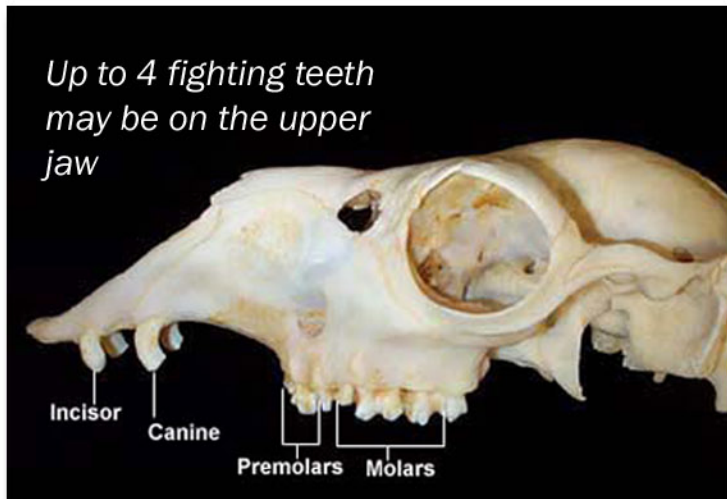

International Camelid Institute

Removal of Fighting Teeth



Photos courtesy of: Colorado State University

1. All males should be checked for fighting teeth starting at age 18 months; when they do appear, it is advisable to remove them at least yearly as they can cause trauma to other animals or their handlers. Although not as common, females can also develop these teeth and they can be removed in the same manner.
2. The procedure is done using obstetrical wire (aka "o.b." or "giggly" wire) and handles that hold the wire at each end. Both wire and handles are readily available at farm supply stores or veterinary supply sites online.
3. Be sure to have a second person hold the animal's head as still as possible and pull the lip back to avoid cutting it with the wire. Place an approximately 18-inch length of wire in the handles; place the wire behind the hook of the tooth, immediately below the gum line, such that when cutting is started only the tooth is contacted by the wire. Pull taut with the handles and use long, steady strokes until the tooth "pops" off. Some resistance from the animal can actually be a help in keeping the wire tight as you pull back and forth. Repeat the process on all the fighting teeth, which may be as many as three on each side of the mouth.
4. Do not be alarmed if a small amount of blood is visible at the gumline - this is not uncommon and will resolve itself within a few minutes.
5. Review the video at www.icinfo.org/videos. If you have questions on any of the above or are unsure or unable to perform this procedure, contact your veterinarian for assistance. In some cases, sedation of the animal makes the procedure much easier.